

Liver Histology of Male Rat (*Rattus norvegicus*) Feed L-Carnitine Supplement

Anak Agung Istri Mas Padmiswari¹, Putu Indrayoni², Nadya Treesna Wulansari³

¹Bachelor of Applied Acupuncture and Herbal Medicine Study Program, Faculty of Health, Institute of Technology and Health Bali, Bali, Indonesia

²Bachelor of Clinic and Community Pharmacy Program, Faculty of Health, Institute of Technology and Health Bali, Bali, Indonesia

³Bachelor of Food Technology Program, Faculty of Technology, Institute of Technology and Health Bali, Bali, Indonesia

*E-mail: amakagungpadmi@gmail.com

Received: May 21, 2024. Accepted: June 14, 2024. Published: July 29, 2024

Abstract: Obesity is a condition where the body is overweight due to fat accumulation, each exceeding 20-25% of body weight for men and women. L-carnitine is a nutrient that plays a role in transporting fat to the mitochondria to be burned and converted into energy for the body. Sufficient L-carnitine allows the body to burn fat at optimal levels. This research aims to determine the side effects of fed L-carnitine supplements against liver histology. This study used a completely randomized design (CRD) with four groups comprising six albino rats. The treatments were fed orally by distilled water 1 ml/day (Control), P1 fed by L-carnitine supplement dose 100 mg/kg body weight orally 1ml/day, P2 fed by L-carnitine supplement dose 150 mg/kg body weight orally 1ml/day, P3 fed by L-carnitine supplement dose 200 mg/kg body weight orally 1ml/day. Treatments were given to albino rats every day for 90 days. Variables observed measured were lipid degeneration, central vein dilation, and pyknotic nuclei. Data were analyzed with the statistical program (SPSS 22.0 for Windows) with One Way ANOVA. The results showed that feeding L-carnitine supplements in high doses for long periods can damage the liver cells of male rats. The microscopic liver damage statistical analysis showed significant differences ($P < 0.05$) between the control and treatment groups.

Keywords: L-carnitine; Liver; Obesity.

Introduction

Being overweight (obesity) is a health problem. Obesity is currently often referred to as *The New World Syndrome*, and the incidence continues to increase throughout the world. Obesity is when the body is overweight due to fat accumulation, for men and women, each exceeding 20-25% of body weight [1]. Obesity is a risk factor for various diseases, primarily degenerative and metabolic diseases. Obesity has a strong correlation with morbidity and mortality, so it needs serious attention regarding the causes, preventive measures, and treatment efforts [2].

Various ways of treating obesity have been widely researched and implemented, including lifestyle changes, physical activity, dietary adjustments, drugs, surgery, and alternative treatments using traditional and herbal methods [3]. Currently, there are many choices of medications from different groups for weight loss. In general, pharmacotherapy for obesity is divided into drugs that work centrally and those that work peripherally, while based on the duration of use, they are divided into short-term and long-term use. All of these drug classes are effective in reducing weight but will be more effective if combined with intensive lifestyle change therapy [4].

L-carnitine is a nutrient that plays a role in transporting fat to the mitochondria to be burned and converted into energy for the body. Sufficient L-carnitine allows the body to burn fat at optimal levels. Another essential function is that it can control fat and body weight by increasing the body's metabolism and the speed of converting fat and carbohydrates into energy. Together with protein, L-carnitine converts fat into muscle mass. As an antioxidant, L-carnitine inhibits lipid peroxidation and reduces oxidative stress [5]. Several studies say that L-carnitine supplements can reduce excess weight. According to Kalpana and Aruna [6], L-carnitine supplements can reduce obesity if balanced with regular physical activity. L-carnitine can also reduce weight in adults [7]. The journal *The Journal of Physiology* states that giving L-carnitine supplements can increase muscle tone in men [8]. Other research also states that administering an intravenous infusion of a combination of L-carnitine and insulin for 6 hours can increase muscle mass by 13% [9].

The liver is a large and complex organ in the body. The liver occupies most of the right upper quadrant of the abdomen, below the diaphragm, protected by the ribs. The liver is the center of the body's metabolism and has complex functions. One of the functions of the liver is to protect the body against toxic substances through detoxification. Most chemical substances or drugs entering

How to Cite:

Padmiswari, A. A. I. . M., Indrayoni, P., & Wulansari, N. T. (2024). Liver Histology of Male Rat (*Rattus norvegicus*) Feed L-Carnitine Supplement. *Jurnal Pijar Mipa*, 19(4), 693–697. <https://doi.org/10.29303/jpm.v19i4.6900>

the digestive tract will pass through the liver, the central metabolic organ [10]. The liver is an organ that plays an essential role in the human body. Metabolism between all food components occurs in the liver. The liver is the primary site of synthetic, catabolic, and detoxification activity in the body. In addition, the liver is also involved in the excretion of blood pigments. Kupffer cells in the liver are also involved in the immune response. Liver damage can be caused by various factors, including viruses, alcohol, and drugs (such as isoniazid, aspirin, and tetracycline). This active ingredient can cause liver function disorders in the form of carcinoma or cirrhosis [11]. All liver injuries cause the same pathological features: degeneration and intracellular accumulation, necrosis, inflammation, regeneration, and fibrosis [12].

Based on the above, the author is interested in conducting an experimental study to see the effect of giving L-carnitine supplements on the liver histology of male mice.

Research Methods

The design used in this research was a Completely Randomized Design (CRD) with one control group and three treatment groups. This study used 24 male mice; each treatment consisted of 6 males. In the control group (K) they were given distilled water orally as much as 1 ml/day, treatment 1 (P1) was given L-carnitine supplement at a dose of 100 mg/kg body weight orally as much as 1 ml/day, treatment 2 (P2) was given L-carnitine supplement with a dose of 150 mg/kg B.W. orally, 1 ml/day, treatment 3 (P3) was given L-carnitine supplement at a dose of 200 mg/kg B.W. orally, 1 ml/day. Treatment was given for 90 days [13].

This research was carried out for six months, from January to June 2023. The study was carried out at the Histology Laboratory, Faculty of Medicine, Udayana University, and the Biomedical Laboratory of the Bali Institute of Technology and Health.

In this study, acclimatization was carried out before treatment. Mice were acclimatized for seven days in plastic tubs lined with husks and covered with a wire lid. Mice were given commercial feed, namely CP 551 pork feed in pellets, 20 g/day, and drank tap water *ad libitum*.

Liver histology incisions were made using the paraffin method. Mice were dissected, and their livers were removed on the 91st day [14]. The fixative solution used was 10% buffered formalin and bouin. Staining using Hematoxylin EhrlichEosin. The variable observed in this study was microscopic liver damage.

Data was analyzed quantitatively using a computer statistical program (SPSS 22.0 for Windows). To see the influence due to treatment, the One Way Anova test was carried out. If there are significant results, proceed with Duncan's multiple range test with the degree of confidence used being 5% ($P < 0.05$).

Results and Discussion

Statistical Analysis of the Amount of Microscopic Liver Damage

The effect of L-carnitine supplementation on the liver histology of male mice can be seen in Table 1. The microscopic liver damage statistical analysis showed significant differences ($P < 0.05$) between the control and treatment groups.

Table 1. Average Amount of Microscopic Damage to the Liver of Male Rats Given L-carnitine Supplements

Parameter	Treatment			
	K	P1	P2	P3
Fatty Degeneration	0.00±0.00a	0.33 ± 0.52a	1.83 ± 2.23a	8.17±3.60b
Central Vein Dilation	0.00±0.00a	0.50±0.55a	10.50±2.43b	19.83±5.45c
Picnotic Core	0.00±0.00a	0.83 ± 0.98a	12.33±4.50b	15.17±6.37b

Note: different letters in one row indicate significantly different results at the 5% test level

K = given oral distilled water 1 ml/day

P1 = given L-carnitine supplement at a dose of 100 mg/kg bw orally, 1 ml/day

P2 = given L-carnitine supplement at a dose of 150 mg/kg bw orally, 1 ml/day

P3 = given L-carnitine supplement at a dose of 200 mg/kg bw orally, 1 ml/day

The significant difference between the control and treatment groups shows that giving L-carnitine supplements up to a dose of 200 mg/kg bw can cause damage to the liver cells of male mice. From the results of the histology section with HE staining in Figure 1, it can be seen that normal liver cells are in the control group. In the P1 group, liver cells began to experience fatty degeneration. At P2, liver cells were seen experiencing dilation of the central vein and several pyknotic cell nuclei. At P3, liver cells are seen experiencing fatty degeneration, central vein dilation, and pyknotic cell nuclei.

The results showed that microscopic damage to the livers of male mice given L-carnitine supplements was

more significant at higher doses. This is thought to be caused by the infiltration of inflammatory cells into hepatocytes and is related to the body's response to various disorders through the activation of thermoregulatory factors. The body suffering from inflammation releases multiple types of biochemical compounds, including different types of glucocorticoid hormones and cytokines. The released cytokines play an essential role in the body's efforts to maintain inflammatory homeostasis. When inflammation occurs, cytokine secretion increases, and the inflammatory response increases.

Furthermore, in chronic inflammation, the protective proteins produced by inflammation become

uncontrolled, thereby damaging various types of cellular proteins and increasing the frequency of apoptosis and tissue necrosis [11]. If the toxic compound that attacks is

too large to be harmful to the liver, it will cause liver tissue degeneration. Necrosis then occurs and can damage liver tissue [15].

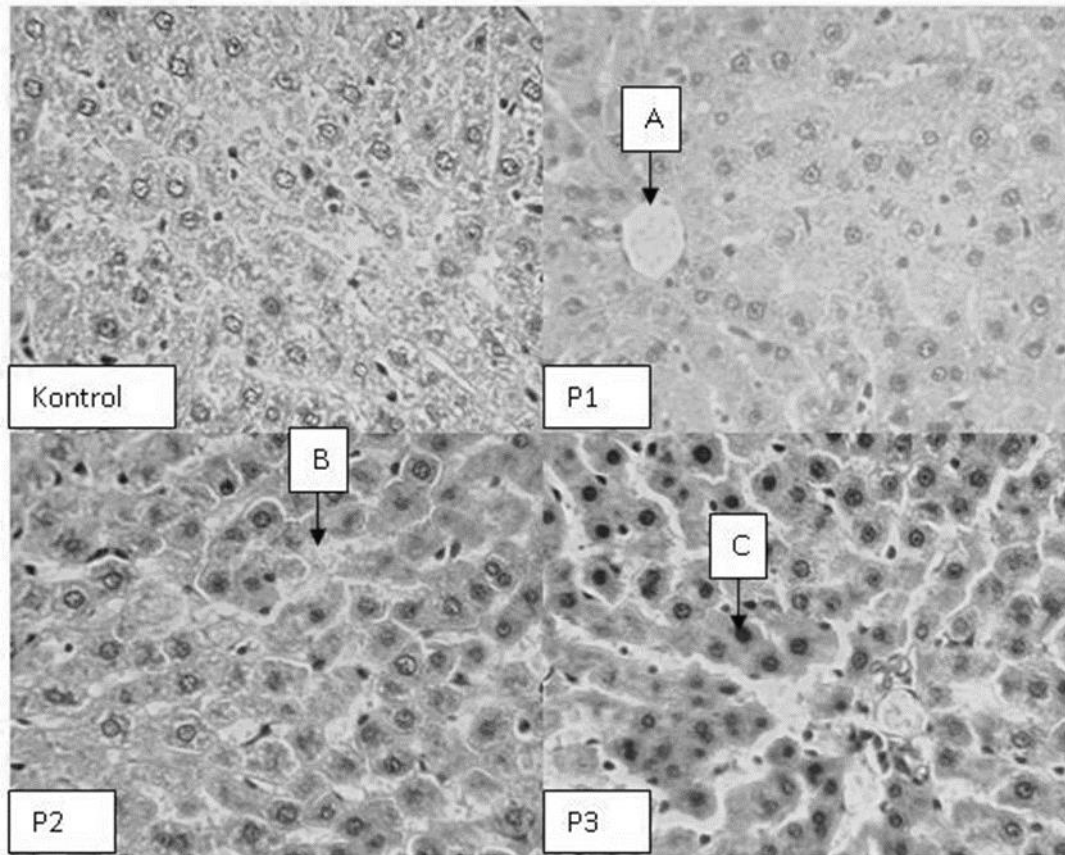


Figure 1. Histology of Liver Cells in Male Rats Given L-carnitine Supplements

Information:

- K = given oral distilled water 1 ml/day
- P1 = given L-carnitine supplement at a dose of 100 mg/kg bw orally, 1 ml/day
- P2 = given L-carnitine supplement at a dose of 150 mg/kg bw orally, 1 ml/day
- P3 = given L-carnitine supplement at a dose of 200 mg/kg bw orally, 1 ml/day
- A= fat degeneration
- B = widening of the central vein
- C= pyknotic nucleus

In the liver histology of the treatment group, damage was found in the form of fatty degeneration, widening of the central veins, and pyknotic nuclei due to the administration of L-carnitine supplements. Fat degeneration can occur due to disturbances in fat metabolism, such as disturbances in mitochondrial function hypoxia, which can inhibit fat oxidation, which later enters the cells. It can also be caused by protein malnutrition. Cell degeneration usually occurs due to a lack of food, oxygen in the tissue, intoxication, and tissue ageing. If fatty degeneration occurs continuously, later hepatocytes can experience necrosis [16]. Fatty acids in mitochondria are used to produce ATP by β -oxidation after being transported by excessive doses of L-carnitine supplements, which are thought to result in negative feedback that can disrupt mitochondrial function so that liver cells experience fatty degeneration. One of the functions of mitochondria is as an organ of cellular respiration. Therefore, disruption of mitochondrial function is thought to cause fatty

degeneration, inhibiting fatty acid oxidation. By inhibiting oxidation, fatty acids accumulate in liver cells and cause fatty liver cells [17].

In this study, damage was found in the form of widening of the central veins; this is thought to be caused by the high fatty acid content in the L-carnitine supplement. These endogenous molecules synthesized in the human body remain a subject of great interest because they are principally involved in energy production by oxidizing highly fatty acids. L-carnitine is a supplement that has received attention for many years. The role of L-carnitine and its derivatives in carbohydrate and lipid metabolism continues to be the subject of research [18]. When circulating L-carnitine levels increase, for example, through oral supplement consumption, L-carnitine reabsorption becomes more concentrated and causes increased L-carnitine excretion [19]. Dilation of the central vein is the beginning of liver tissue damage caused by the lysis of endothelial cells in the central vein [20]. That

blood will flow through the sinusoids and into the central vein [21]. This provides maximum exchange area between blood and hepatocytes in the liver. Blood carries metabolic results from hepatocytes, including toxic metabolic products. According to Marya [22], the results of this metabolism will accumulate in the central vein and cause lysis of the endothelial cells in the central vein. This lysis of endothelial cells causes an increase in the diameter of the central vein.

Necrosis in cells begins with pyknotic changes in the cell nucleus. This research also found damage in the form of pyknotic nuclei. Cells whose core is very dark and compact and covers all parts of the cell nucleus are pyknotic cells. Cells that will later experience pyknosis will see chromatin collected as a single globule, and the nucleus will look dark. Pyknosis can occur due to damage within the cell, namely damage to the membrane, which is then followed by the Golgi apparatus and mitochondria, which will result in the cell no longer being able to eliminate water and triglycerides so that they accumulate in the cytoplasm. Cells [23]. Damage to liver cells is thought to be caused by excessive doses given so that it is toxic to the body, especially to the liver. According to Amalina [24], damage to liver cells due to poisonous substances is influenced by several factors, such as the type of chemical substance, the dose given, and the length of time the substance is administered. The higher the concentration of a given compound, the greater the toxic response it will cause. Research results show that the bioavailability of L-carnitine from oral supplements (5-6 grams) varies between 14-18% of the total dose [25].

Conclusion

The microscopic liver damage statistical analysis showed significant differences ($P < 0.05$) between the control and treatment groups. High doses of L-carnitine supplements over a long period can cause damage to the liver cells of male mice. Research development can be carried out regarding the safe dose of consuming L-carnitine and observing the histology of other body organs.

References

- [1] ERCHO, N. C. (2014). Hubungan obesitas dengan kadar LDL dan HDL pada mahasiswa preklinik Fakultas Kedokteran Universitas Lampung Tahun 2013.
- [2] Pradana, A., Seno, K., & Puruhita, N. (2014). *Hubungan antara indeks massa tubuh (IMT) dengan nilai lemak visceral (Studi kasus pada mahasiswa kedokteran Undip)* (Doctoral dissertation, Faculty of Medicine Diponegoro University).
- [3] Hardani, E., Lestariana, W., & Susetyowati, S. (2014). Efek pemberian ekstrak teh hijau (*Camellia sinesis* (L) O. Kuntze) var. *Assamica* terhadap total lemak tubuh dan profil lipid wanita dewasa overweight dan obesitas. *Jurnal gizi klinik indonesia*, 10..
- [4] Caterson, I. D. (2009). Medical management of obesity and its complications. *Ann Acad Med Singapore*, 38(1), 22-7.
- [5] Theresa, A., Sukohar, A., & Wardhana, M. F. (2023). Nutrasetikal dalam Pengelolaan Obesitas. *Medical Profession Journal of Lampung*, 13(4), 472-478.
- [6] Kalpana, A., & Aruna, D. (2012). Effects of L-carnitine [Neutraceutical] in weight management among overweight and obese adults of age between 20–45 yrs—A comparative study in Chennai and Tirupathi. *Int J Sci Res Publ*, 2, 1-5.
- [7] Pooyandjoo, M., Nouhi, M., Shab-Bidar, S., Djafarian, K., & Olyaeemanesh, A. (2016). The effect of (L-) carnitine on weight loss in adults: a systematic review and meta-analysis of randomized controlled trials. *Obesity reviews*, 17(10), 970-976.
- [8] Wall, B. T., Stephens, F. B., Constantin-Teodosiu, D., Marimuthu, K., Macdonald, I. A., & Greenhaff, P. L. (2011). Chronic oral ingestion of L-carnitine and carbohydrate increases muscle carnitine content and alters muscle fuel metabolism during exercise in humans. *The Journal of physiology*, 589(4), 963-973.
- [9] Stephens, F. B., Constantin-Teodosiu, D., Laithwaite, D., Simpson, E. J., & Greenhaff, P. L. (2006). Insulin stimulates L-carnitine accumulation in human skeletal muscle. *The FASEB journal*, 20(2), 377-379.
- [10] Sherwood, L. (2020). Fisiologi manusia dari sel ke sistem.
- [11] Utomo, Y., Hidayat, A., Dafip, M., & Sasi, F. A. (2012). Studi histopatologi hati mencit (*Mus musculus L.*) yang diinduksi pemanis buatan. *Indonesian Journal of Mathematics and Natural Sciences*, 35(2).
- [12] Setiani, N. N. G., Loho, L., & Lintong, P. (2016). Gambaran histopatologik hati tikus wistar (*Rattus norvegicus*) yang diinduksi monosodium glutamate (msg) dan diberikan sari air bawang daun (*Allium fistulosum L.*). *eBiomedik*, 4(2).
- [13] Al-Daraji, H. J., & Tahir, A. O. (2014). Effects of dietary L-carnitine supplementation on testicular histology of Iraqi drakes.
- [14] Rahmi, H. (2009). Studi hematologis dan histopatologis organ pada tikus yang diinduksi kuinin sebagai uji potensi metabolik angkak. *Skripsi. Institut Pertanian Bogor: Fakultas Matematika dan Ilmu Pengetahuan Alam. Departemen Biokimia*.
- [15] Muthiadin, C., Zulkarnain, Z., & Hidayat, A. S. (2020). Pengaruh pemberian tuak terhadap gambaran histopatologi hati mencit (*Mus musculus*) ICR jantan. *Jurnal Pendidikan Matematika dan IPA*, 11(2), 193-205.
- [16] Pramesti, N. K. T., Wiratmini, N. I., & Astiti, N. P. A. (2017). Struktur Histologi Hati Mencit (*Mus musculus L.*) Setelah Pemberian Ekstrak Daun Ekor Naga (*Rhapidophora pinnata* Schott). *Jurnal Simbiosis*, 2, 43-46.
- [17] Setiani, N. N. G., Loho, L., & Lintong, P. (2016). Gambaran histopatologik hati tikus wistar (*Rattus norvegicus*) yang diinduksi monosodium glutamate

- (msg) dan diberikan sari air bawang daun (*Allium fistulosum* L.). *eBiomedik*, 4(2).
- [18] Taylor, S. A., & Miloh, T. (2018). Adolescent Alcoholic Liver. *Alcoholic Liver Disease, An Issue of Clinics in Liver Disease*, 23(1), 51-54.
- [19] Budi Pramono, Y. (2022). Buku Monograf: Mengapa Belum Mendapat Keturunan? Pola Makan dan Pola Hidup Sehat untuk Mendapatkan Keturunan.
- [20] Madihah, R. N., Malini, D. M., Faiza, A. H., & Iskandar, J. (2017). Uji toksisitas akut ekstrak etanol kulit buah jengkol (*Archidendron pauciflorum*) terhadap tikus Wistar betina. *Prom Sem Nas Masy Biodiv Indon*, 3, 33-8.
- [21] Hoehme, S., Brulport, M., Bauer, A., Bedawy, E., Schormann, W., Hermes, M., ... & Drasdo, D. (2010). Prediction and validation of cell alignment along microvessels as order principle to restore tissue architecture in liver regeneration. *Proceedings of the National Academy of Sciences*, 107(23), 10371-10376.
- [22] Singh, K. A. R. A. M., & Verma, B. H. A. V. N. A. (2012). Ayurvedic perspectives towards Cerebral palsy. *Journal of Research and Education in Indian Medicine*, 18(3-4), 163-74.
- [23] Simanjuntak, S. J. O., Berata, I. K., Winaya, I. B. O., Setiasih, N. L. E., Sudimartini, L. M., & Susari, N. N. W. (2024). The Effect Of Mimosine From Simplicia of The Lamtoro Leaf on the Histopathological Of White Rats'testis. *Buletin Veteriner Udayana*, 851-860.
- [24] Amalina, N. (2009). *Uji toksisitas akut ekstrak Valerian (Valeriana officinalis) terhadap hepar Mencit Balb/C* (Doctoral dissertation, Medical faculty).
- [25] Flanagan, J. L., Simmons, P. A., Vehige, J., Willcox, M. D., & Garrett, Q. (2010). Role of carnitine in disease. *Nutrition & metabolism*, 7, 1-14.